


## CASE REPORT

ERCP performed  
with a single-use  
duodenoscope

# ERCP, ENDOBILIARY RFA AND STENTING



**Khanh Do-Cong Pham,  
MD, FASGE**

Consultant Endoscopist  
and Gastroenterologist.  
Dep. of Medicine,  
Haukeland University  
Hospital, Norway

### PATIENT HISTORY

A 22-year-old man with a previous history of ulcerative colitis and primary sclerosing cholangitis was diagnosed with a Klatskin tumor, Bismuth IV, involving the whole left liver and the extra hepatic bile ducts. He was initially treated with repeated ERCP, and biliary stenting and palliative chemotherapy. To control the intraductal tumor growth, endobiliary radiofrequency ablation (RFA) was later added. Over the course of time, he was admitted several times due to cholangitis, and the bile ducts were colonized with multiresistant *Klebsiella pneumoniae*.

### PROCEDURE

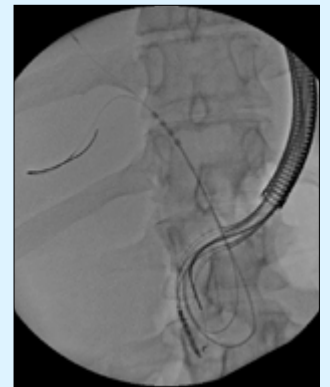ERCP was performed using Ambu® aScope™ Duodeno, a single-use duodenoscope. It was performed under general anesthesia, due to anxiety and tumor-related pain. The insertion and positioning of the aScope Duodeno into the duodenum, cannulation of the bile duct and insertion of two guide wires were easily achieved. RFA and placement of plastic stents, which are usually the most challenging parts of the procedure, were uncomplicated (Figure 1).

### OUTCOME

For this patient, the single-use duodenoscope was necessary to avoid cross-contamination of multiresistant bacteria and to reduce the risk of infections during chemotherapy. The combined treatment of RFA and chemotherapy slowed the tumor growth and reduced the episodes of cholangitis, resulting in prolonged survival.

### CONCLUSION

The translucent tip of the aScope Duodeno was a very useful feature for instrumentation inside the bile ducts. The water irrigation was also notably much more powerful, and the noise level was unusually low compared to reusable endoscopes. Overall, the clinical performance was such that we were not cognizant of the fact that we were using a single-use endoscope during the procedure.



*Figure 1: The radiotranslucent tip made it easy to position the RF ablation probe*

# Ambu

Ambu A/S  
Baltorpbakken 13  
2750 Ballerup  
Denmark  
Tel.: +45 7225 2000  
ambu.com