


## CASE REPORT

ERCP performed  
with a single-use  
duodenoscope

# PLASTIC STENT PLACEMENT IN PATIENT WITH CHOLESTASIS



**Prof. Dr. Arthur Schmidt**  
Freiburg University Hospital  
Universitäts Klinikum Freiburg  
Clinic for Internal Medicine II,  
Germany

### PATIENT HISTORY

A 56-year-old patient with a history of necrotizing pancreatitis was scheduled for ERCP due to cholestasis. A prior MRI scan had shown a compression of the distal common bile duct due to walled-off necrosis.

### PROCEDURE

An ERCP was performed with the Ambu® aScope™ Duodeno, a single-use duodenoscope. Passage into the duodenum was achieved without any problems, and the endoscope made a stable position and good visualization of the papilla possible. Wire-guided cannulation of the papilla was achieved in the first attempt. A cholangiogram showed longer stenosis of the distal common bile duct, which was most likely due to compression by the walled-off necrosis in the pancreatic head.

The transparent distal tip of the endoscope allowed excellent radiographic visualization of the distal common bile duct (Figure. 1).

After sphincterotomy, a 10F plastic stent was inserted to achieve biliary drainage.

### OUTCOME

After the ERCP, the patient received transgastric drainage and multiple sessions of necrosectomy, which resulted in complete resolution of the walled-off necrosis. The patient was discharged and was scheduled for removal of the biliary stent and the transgastric drains.

### CONCLUSION

ERCP with the Ambu® aScope™ Duodeno single-use endoscope is feasible. X-ray transparency of the distal tip allows excellent fluoroscopic visualization of the distal common bile duct.

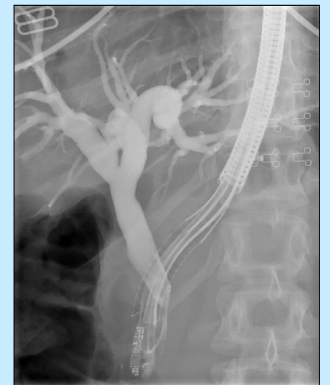


Figure 1: ERCP with single-use duodenoscope

# Ambu

Ambu A/S  
Baltorpbakken 13  
2750 Ballerup  
Denmark  
Tel.: +45 7225 2000  
ambu.com