

## CASE REPORT

ERCP performed  
with a single-use  
duodenoscope

# RARE CASE OF FUNCTIONAL STENOSIS OF THE EXTRAHEPATIC BILE DUCT



**Prof. Dr.  
Mark Ellrichmann,  
MaHM**

University Hospital  
Schleswig-Holstein,  
Campus Kiel, Germany

### PATIENT HISTORY

A 71-year-old man presented to our ER with recurrent abdominal pain in the right upper quadrant, accompanied by jaundice and acholic stool. The lab test revealed significantly increased cholestasis parameters, with increased C-reactive protein and leucocytes. An abdominal ultrasound showed a dilated common bile duct (CBD) in the proximal extrahepatic third close to the liver hilum, with prominent intrahepatic bile ducts; the distal two-thirds displayed slim or even collapsed, with an S-shaped deformation. Astonishingly, an increased kinking of the CBD was observed under deep inspiration, with a functional stricture as potential cause of the cholestasis. Extraductal tumors or adhesions were not observed. A CT scan confirmed the ultrasound results; again no extraductal pathology was delineated. As a side diagnosis, blood cultures and skin swaps were positive for Vancomycin-resistant Enterobacteriae (VRE). Based on the lab results and ultrasound morphology, the diagnosis of a functional CBD stricture with acute cholangitis was made.

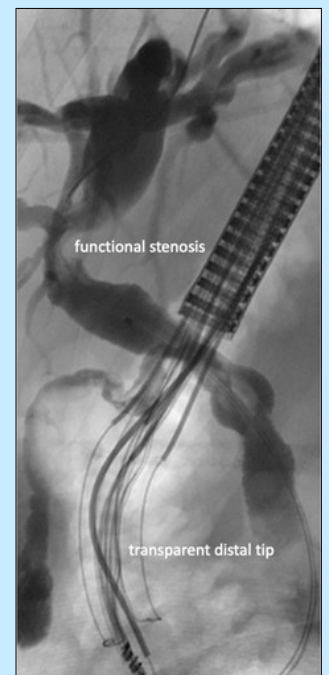
### PROCEDURE

The ERCP was performed using Ambu® aScope™ Duodeno, a single-use duodenoscope. Due to the excellent maneuverability of aScope Duodeno, the descending part of the duodenum was easily accessible, enabling an optimal short position in front of the papilla (Figure 1).

The papillary orifice could be clearly delineated. After intubation of the distal part of the CBD, contrast medium was injected visualizing the S-shaped contortion of approximately the middle third of the CBD, which significantly aggravated under inspiration. Notably, due to the transparency of the distal tip of the duodenoscope, the whole track of the CBD could be followed without adjusting the X-ray apparatus or the patient's position. Under expiration, during which the bending of the CBD stretched, a guide wire was passed over the functional stricture into the left hepatic duct. Thereafter, a plastic stent of 10 Fr and 12 cm was inserted into the CBD up to the liver hilum to span the functional stricture and to ensure drainage.

### OUTCOME

Clinical follow-up of the patient proceeded without any complications. Infection parameters normalized under antibiotic therapy; cholestasis parameters declined immediately after ERCP with proper drainage. The patient was discharged seven days after admission. Another ERCP with stent exchange and, potentially, insertion of a fully covered metal stent is scheduled ten weeks after the first ERCP.



*Figure 1: ERCP with single-use duodenoscope in short position in front of the papilla.*

## CASE REPORT

ERCP performed  
with a single-use  
duodenoscope

### CONCLUSION

Based on the case presented and current literature (see addendum), single-use duodenoscopes can be employed in the majority of ERCP cases of all ASGE complexity grades, with a low rate of conversion to reusable duodenoscopes. In our center, single-use duodenoscopes are used either in immunocompromised patients (after liver Tx, immunosuppressive medication, HIV infection, etc.) or in patients contaminated with multi-drug resistant organisms. The latter was the indication for using a single-use duodenoscope in the case presented.

For the use of single-use endoscopes in general, several topics need to be discussed from a clinical point of view:

- (i) Functionality of the scopes in comparison to reusable scopes
- (ii) Patient stratification: In which patients should a single-use scope be used?
- (iii) Costs and reimbursement

### ADDENDUM

Clinically relevant infections triggered by the use of flexible endoscopes have become the focus of clinical and scientific interest in the literature. The endoscopy-associated infections can be categorised into two groups:

1. Endogenous infections;
2. Exogenous infections.

Endogenous infections are triggered by the spread of the patient's own local flora and mainly involve *Escherichia coli*, *Klebsiella* species, *Enterobacter* species and *Enterococci*. The resulting endogenous infections are, for example, pneumonia due to aspiration of secretions in sedated patients or due to the spread of germs from the flora of the oral cavity during flexible bronchoscopies. Furthermore, cholangitis and bacteraemia have been reported in patients with biliary obstruction after ERCP.

In order to reliably reduce the rate of contamination, and thus exogenous infections, the use of single-use duodenoscopes obtained high priority. In an updated safety warning dated 24.07.2020 (<https://fda.gov/medical-devices/safety-communications/fda-recommending-transition-duodenoscopes-innovative-designs-enhance-safety-fda-safety-communication>), the FDA (Federal Drug Administration of the US) recommended the use of single-use duodenoscopes.

# Ambu

Ambu A/S  
Baltorpbakken 13  
2750 Ballerup  
Denmark  
Tel.: +45 7225 2000  
ambu.com